

February 9, 2021

PRESS RELEASENagoya City University, a Municipal University Corporation
PharmaBio Corporation

First-in-Human trial on human (autologous) iris pigment epithelial cell sheet transplantation for myopic chorioretinal atrophy has begun recruiting patients at Nagoya City University Hospital.

On February 3, 2021, Nagoya City University (Nagoya, Japan; Chairman and President , Kenjiro Kori) concluded an agreement with PharmaBio Corporation (Nagoya, Japan; Managing director and CEO, Hitoshi Kusano) to conduct a “clinical trial on human (autologous) iris pigment epithelial (IPE) cell sheet transplantation for myopic chorioretinal atrophy”.

Severe stage of ‘myopic chorioretinal atrophy’ (also known as ‘myopic macular atrophy’) is one of the serious fundus diseases related to high myopia (Fig. 1.), a condition in which the axial length (length of the eyeball in the front-back direction [from the cornea to the retina]) increases for some reason.

In addition to myopic chorioretinal atrophy, high myopia can cause a number of related fundus diseases such as myopic choroidal neovascularization (*1) and myopic traction maculopathy (*2) (which leads to retinoschisis, macular hole, and macular hole-associated retinal detachment). Among the diseases for which the Visual Impairment Certificate is issued in Japan, myopic chorioretinal atrophy is a causal disease in some of chorioretinal atrophy at rank 5 and some of high myopia at rank 10.¹⁾ Although the pathogenesis of myopic chorioretinal atrophy has not been fully elucidated, it is thought to begin with the axial elongation that accompanies myopia and progress to thinning of the retina (corresponding to a camera film) and the choroid (vascular tissue outside of the retina) and decrease of cell density in retinal pigment epithelium (RPE) (*3), which is an outermost layer of the retina and indispensable to maintaining retinal functions. Resultant functional impairment of RPE causes progression of atrophy of choriocapillaris, the retina, and RPE itself. Finally, severe chorioretinal atrophy (myopic macular atrophy associated with Bruch’s membrane defect frequently due to choroidal neovascularization) develops and, when the macula is involved²⁾, visual acuity decreases with gradual expansion of central scotoma with years (Fig. 2.). Since the disease sometimes progresses bilaterally, patients are seriously disabled from daily life, finally leading to social blindness because of no effective treatments at this moment.

Replenishing RPE cells may be a potent strategy for breaking the vicious cycle of atrophy of the retina, RPE, and the choroid. However, it is difficult to harvest the patient’s own RPE cells. Therefore, other methods have been tested to treat age-related macular degeneration, another disease associated with RPE disorder, including autologous transplantation of a suspension (*4) of cultured iris pigment epithelial (IPE) cells harvested and cultured from the iris tissue dissected from the patient’s eye and allogeneic transplantation of a suspension of RPE cells derived from various stem cells. While the safety of these procedures has been proven, the rate of cell engraftment by transplantation in the condition of a cell suspension varies and the efficacy of this therapy in improving and maintaining visual function has not yet been sufficiently verified. Moreover, there is concern over complications associated with cell scattering into the vitreous cavity. It would be ideal to transplant a cell sheet in a single layer, similar to the original state of RPE cells in the eye. But the transplantation of cell sheets produced using an artificial scaffolding has problems such as foreign body reactions and the friability of the sheet. In addition, allogeneic transplantation remains the problem of rejection reaction.

PharmaBio Corporation has been working on the development of an (autologous) iris pigment epithelial (IPE) cell sheet, using a method for manufacturing cell sheets attaching onto a self-produced membrane composed of extracellular matrix (*5) resembling to Bruch's membrane underlying RPE in the eye. This method was developed originally by Dr. Tsutomu Yasukawa, an associate professor at the Department of Ophthalmology and Visual Science, Nagoya City University Graduate School of Medical Sciences (Nagoya, Japan). This technique is expected to have the following advantages: [1] improved cell engraftment rate, [2] exhibition of functions by transplanted cells (leading to improving and maintaining visual function), [3] reduced risk of complications, [4] avoidance of the risk of rejection reaction. In this exploratory trial, the safety and the efficacy of this technique will be evaluated in a small number of cases. If favorable results are obtained in the clinical trial, we will immediately apply for marketing approval so as to deliver this therapy to patients who are suffering from high myopia-associated macular atrophy as soon as possible.

- 1) Wako R, Yasukawa T, et al. Journal of Japanese Ophthalmological Society (Nippon Ganka Gakkai Zasshi). 118:495-501, 2014
- 2) Ohno-Matsui K, Kawasaki R, Jonas JB, et al. Am J Ophthalmol. 159:877-883.e7, 2015

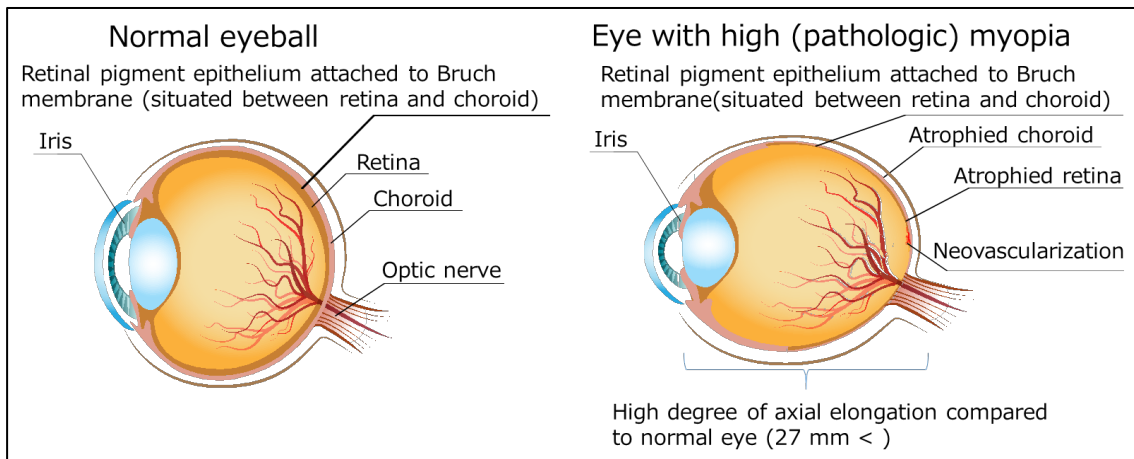
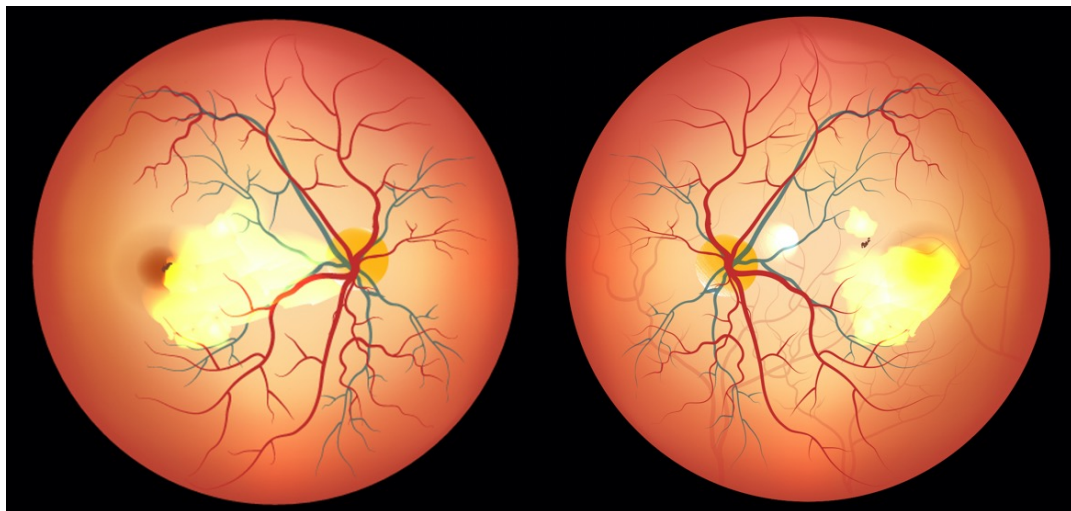


Fig.1. Normal eyeball and eye with high (pathologic) myopia



In severe cases of myopic chorioretinal atrophy (macular atrophy), atrophy (yellowish-white part) tends to develop and spread, leading to an extensive blind spot in the center of the visual field.

Fig. 2. Myopic chorioretinal atrophy

[Explanation of Terminology]

(*1) **Myopic choroidal neovascularization:** In some of eyes with the condition, in which axial elongation is accompanied by breach of the Bruch's membrane that supports overlying RPE, abnormal (new) vessels originate from the choroid and invades the subretinal space as pathologic manifestation of wound healing response. Plasma leakage and bleeding from choroidal neovascularization may cause metamorphopsia and central scotoma. Intravitreal anti-vascular endothelial growth factor therapy before irreversible damage can improve and maintain vision in many cases. However, in some cases, macular atrophy is complicated and progresses thereafter.

(*2) **Myopic traction maculopathy:** Because of backward displacement of the retina with axial elongation, the intraocular gel (vitreous body) that adheres to the retina sometimes generates counteracting frontward retinal traction. This force may cause the retinoschisis, macular hole, and macular hole-associated retinal detachment, which will, if untreated, result in visual acuity decrease, visual field defect, and blindness. Recently, many cases are treatable by vitreous surgeries.

(*3) **Retinal pigment epithelium (RPE):** RPE is a monolayer of pigmented cells that is located at the outermost side of retinal multilayers. It supports highly sophisticated retinal functions to sense light through the maintenance of photoreceptors in the retina, the transport of nutrients and waste products, and the blood retinal barrier to restrict unnecessary humoral factors from the choroid. Thus RPE is indispensable to maintain retinal functions and its atrophy leads to the atrophy of the choriocapillaris (microvasculature of the choroid) and photoreceptor cells of the retina.

(*4) **Suspension:** The term, 'suspension' generally means a liquid that contains solid particles. Nevertheless, in this case, it is a liquid that contains dispersed cells, indicating the technique of transplantation not in the form of a cell sheet but in the condition of discrete cells.

(*5) **Extracellular matrix:** The extracellular matrix is made of the components that are necessary biochemically and mechanically (e.g. cell adhesion, specific tissue formation, and resistance against external force). These components are produced by cells, including collagen fibers, elastic fibers, and other molecules.

[Contact]

**Nagoya City University Graduate School of Medical Sciences,
Department of Ophthalmology and Visual Science**

Yuichiro Ogura, Professor

Tsutomu Yasukawa, Associate Professor

1, Kawasumi, Mizuho-cho, Mizuho-ku, Nagoya, Aichi 467-8601, Japan

Telephone: +81-52-853-8251 FAX: +81-52 841-9490

E-mail: ogura@med.nagoya-cu.ac.jp

yasukawa@med.nagoya-cu.ac.jp

PharmaBio Corporation

Hitoshi Kusano, Managing Director & Chief Executive Officer

Seiji Shibata, Manager, Pharmaceutical Promotion Department

2-1-3 Nihonbashi, Chuo-ku, Tokyo 103-0027, Japan

Urbannet Nihonbashi 2-chome Building 10F,

Telephone: +81-3-6205-4101 FAX: +81-3-6205-4102

E-mail: ir_admin@pharmabio.co.jp

[Press inquiries]

Nagoya City University Hospital, Management Division

1, Kawasumi Mizuho-cho, Mizuho-ku, Nagoya, Aichi 467-8602, Japan

Telephone: +81-52-858-7113

E-mail: hpkouhou@sec.nagoya-cu.ac.jp

PharmaBio Corporation

Same as above